Reconstruction of the Midface and Maxilla

Mark G. Shrime, MD, FACS, Ralph W. Gilbert, MD, FRCSC*

KEYWORDS

• Maxilla • Reconstruction • Iliac crest
• Fibula • Scapula • Local flap

The functional and aesthetic importance of the maxilla is difficult to overestimate. The central face, nose, upper lip, orbit, malar region, and cheek form the centerpiece of facial identity. In addition, the maxilla mitigates transmission of occlusal forces to the cranium; supports the upper portion of the face, the cranial vault, and the brain; anchors the dentition; and forms the framework for the soft tissues of the face and muscles of facial expression. Loss of tissue volume or structural integrity in this region has far-reaching implications on mimesis, function, and aesthetic appearance.

Tumors affecting this region are disparate in pathology and behavior: squamous cell carcinomas arising from the epithelial lining of the palate, nasal cavity, and sinuses; primary orbital tumors; neoplasms of the minor salivary glands dispersed throughout the maxilla; midline destructive lesions; and mucosal melanomas make up the majority of the neoplasms affecting this region, in addition to benign odontogenic and nonodontogenic tumors and metastases from distant sites.[1–3] As a result, treatment varies, and the resultant defects from surgical resections span the spectrum from simple excisions to wide-field resections limited only by the dura above and the tongue below. Morbidity from these resections can be significant, not only affecting appearance and the structural integrity of the head but also engendering functional defects in swallowing, taste, speech, and vision.

Reconstruction of these defects, therefore, has been a matter of significant controversy. The goals of reconstruction must include the replacement of native tissue, the creation of a barrier between the oral cavity and structures superior to it, the reconstruction of maxillary architecture and the restoration of its structural integrity, the restitution of midfacial contour, the re-establishment of a scaffold against which the soft tissues of the face may be suspended, and, finally, the restoration of dentition and the return of normal masticatory function. Traditionally, maxillectomy defects have been reconstructed with prosthetic obturation. This reconstructive technique has many advantages, including the ability to restore contour, function, and a barrier between the oral cavity and the regions superior to it. For well over a century, obturation was the standard reconstruction for maxillary defects—Grover Cleveland, the 22nd and 24th President of the United States, famously was fitted with a rubber prosthesis after Dr. Joseph Bryant resected a malignant lesion on his hard palate in 1893.[4] Despite its advantages, however, obturation has its own drawbacks, including the need for manual dexterity to maintain the prosthetic, the difficulty of obtaining perfectly leak-tight separation of the oral cavity from the nasal cavity and sinuses, the problem—depending on the amount of tissue resected—with long-term retention, constant irritation, and, of greatest import, decreased patient satisfaction.[5]

In an attempt to mitigate these difficulties, reconstructive options have spanned the entire reconstructive ladder, with split- and full-thickness skin grafts, local flaps, pedicled regional flaps, and microvascular free tissue transfer all advocated. The choice of reconstruction depends most intimately on the size and location of the defect. The advent of microvascular reconstructive techniques has made the maxilla a region of significant innovation and advancement. Local

Wharton Head and Neck Centre, Princess Margaret Hospital, Toronto, Ontario, Canada
* Corresponding author.
E-mail address: ralph.gilbert@uhn.on.ca (R.W. Gilbert).

Facial Plast Surg Clin N Am 17 (2009) 211–223
doi:10.1016/j.fsc.2009.01.008
1064-7406/09/$ – see front matter

flaps can be used for small defects of the palate where the defect size would not allow prosthetic retention. Larger defects involving bone and those with loss of structural integrity are candidates for composite flap reconstruction.

CLASSIFICATION SYSTEMS OF MAXILLARY DEFECTS

Because of the complexity of the possible defects involved in the maxilla, multiple classification schemes have been proposed to aid in the choice of reconstructive options. Each scheme approaches the problem from a slightly different angle and no single scheme has achieved universal acceptance.

The earliest and simplest classification scheme for diseases of the maxilla was proposed by Öhngren in 1933. Because Öhngren did not believe that radical extirpation of maxillary tumors was effective therapy, favoring radiation treatment instead, his concern was prognostic and, as a result, his classification scheme placed little emphasis on maxillectomy defects. Instead, he famously split the maxilla in two, based on an imaginary line running from the angle of the mandible to the medial canthus of the ipsilateral eye;[6] tumors occurring anteroinferior to that line were believed to be "topographically more benign;" those posterosuperior to it were more lethal.[7]

The first classification to take surgical defects into account was proposed by Aramany in 1978.[8] Six different types of maxillectomy defects were identified:

1. The resection in the class I defect did not cross the midline and preserved the teeth on the contralateral side of the maxillary arch.
2. Class II defects were more limited, with preservation of the contralateral maxillary teeth, the central incisors, and, if possible, the canines and premolars on the resection side.
3. Class III defects involved only the central hard palate, without resection of any teeth.
4. Class IV defects crossed the midline, preserving only the posterior teeth on the contralateral side.
5. Class V defects involved resections of the posterior portion of the maxillary arch, with preservation of the mesial abutment teeth on both sides.
6. Finally, class VI defects involved resection of the midline central maxilla, with preservation of the teeth posterior to those used for abutment.

These defects are summarized in **Fig. 1**.

This classification remained the standard for nearly 2 decades, until Spiro and colleagues[7] published a revised schema, based on a retrospective review of 403 maxillectomies performed over a 9-year period. Unlike his predecessor's, Spiro's proposal broke defects down by the procedure performed rather than by resultant tissue loss. Three types of procedures were permitted in this scheme: limited maxillectomy, subtotal maxillectomy, and total maxillectomy (with or without orbital exenteration). Limited maxillectomy was subdivided further into medial, lateral, anterior, and inferior types.

Within the following 4 years, three other methods to classify maxillectomy defects were proposed. In 2000, Brown and colleagues[9] proposed the first classification scheme since Aramany's that focused on tissue loss. This scheme also proposed reconstructive techniques for each defect. In the Brown classification system, appraisal occurs of the vertical (classes 1–4) and horizontal (classes a–c) components of the tissue defect. Class 1 vertical defects cause no oroantral fistula; class 2 defects remain low; class 3 defects are high maxillectomies; and class 4 defects are radical maxillectomies with involvement of the orbit. Horizontal defects remain on one side of the midline without involving the nasal septum (class a), cross the midline or involve the nasal septum (class b), or involve resection of the entire hard palate and alveolar maxilla (class c). This classification scheme and the proposed reconstructive options are shown in **Fig. 2**.

In the same year, Cordeiro and Santamaria[10] expanded on the 1997 Spiro classification scheme, subdividing maxillectomies into partial/limited (type I), subtotal (type II), total with preservation of orbital contents (type IIIa), total with orbital exenteration (type IIIb), and orbitomaxillectomy (type IV). Type I maxillectomies involved resection of only one or two walls of the maxilla, not including the hard palate. Type II defects involved resection of five of the six walls of the maxilla (hard palate, anterior, posterior, lateral, and medial walls), with preservation of the floor of the orbit. Type IIIa defects involved resection of all six walls of the maxilla with preservation of the orbital contents; type IIIb involved sacrifice of those contents. Finally, type IV maxillectomies involved resection of the upper five walls of the maxilla (orbital floor, anterior, posterior, lateral, and medial walls) and the contents of the orbit, with preservation of the hard palate.

Based on experience with 60 patients in the span of 6 years, the investigators proposed various reconstructive options for these four types of maxillectomy defects. The classification

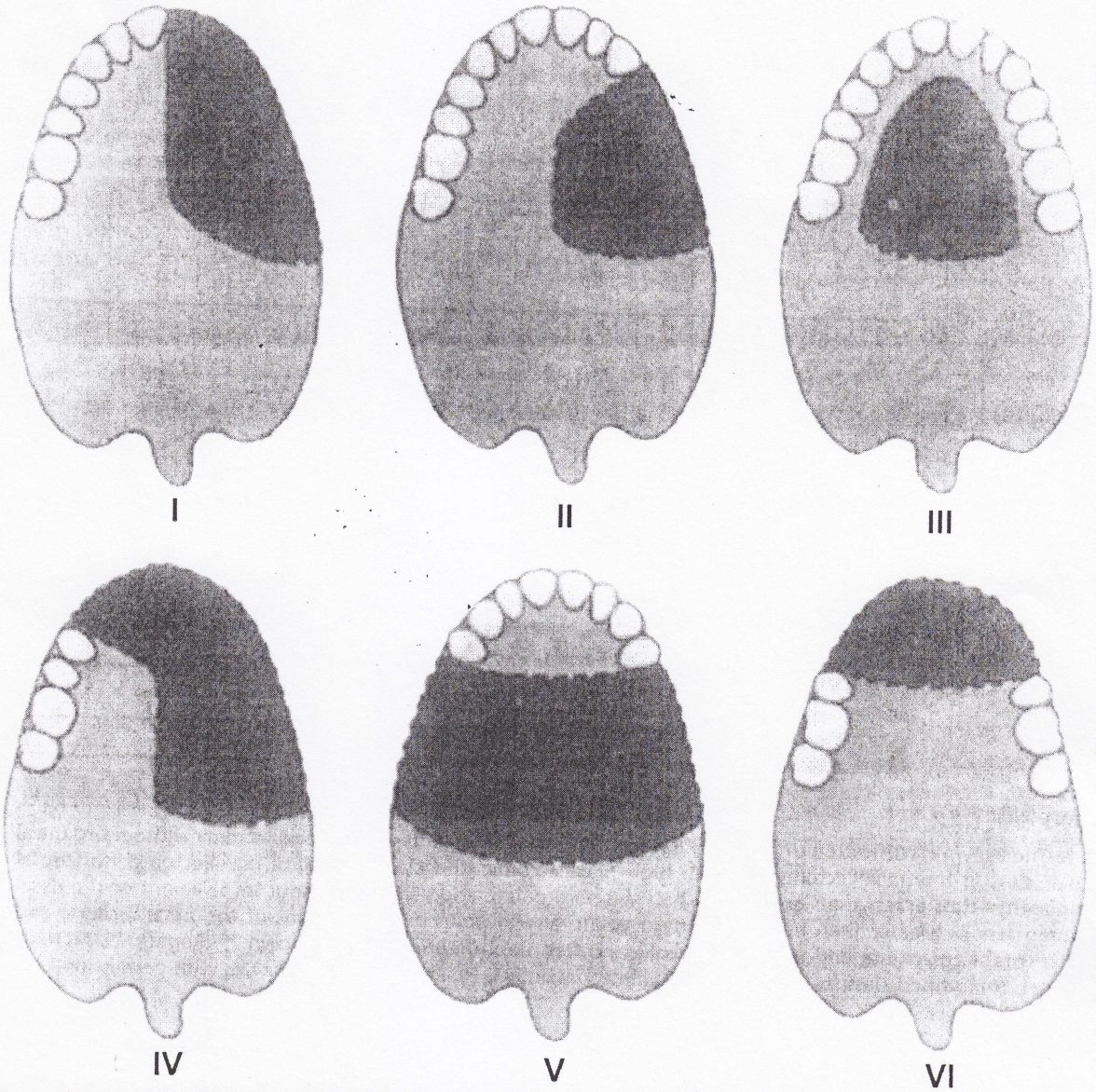

Fig. 1. The Aramany classification of maxillary defects. Class I: midline resection. Class II: unilateral resection. Class III: central resection. Class IV: bilateral anteroposterior resection. Class V: posterior resection. Class VI: anterior resection. (*Reprinted from* Aramany M. Basic principles of obturator design for partially edentulous patients. Part I: classification. J Prosthet Dent 1978;40(5):554–7; with permission.)

scheme and these reconstructive options are summarized in **Table 1**.

In 2001, Okay and colleagues[11] proposed a maxillectomy defect classification system with a view toward the assessment of functional outcome, prosthetic retention, and patient satisfaction. Based on a retrospective review of 47 consecutive maxillectomy defects, this classification scheme also was the first to take the status of the zygomatic arch and orbital floor into direct consideration. In the Okay classification, class Ia defects involve any portion of the hard palate except the tooth-bearing alveolus. Class Ib defects involve any portion of the maxilla with the preservation of both canine teeth. Class II defects involve only one canine (except in the case of transverse anterior palatectomies that resect less than 50% of the hard palate). Class III defects involve the resection of both canines or greater than 50% of the hard palate. Subclasses f (orbital floor) and z (zygomatic arch) also involve resection of those particular structures. Specific to this classification scheme is a focus on reconstructive outcomes: class Ia and Ib defects, for example, can be reconstructed with soft tissue alone whereas class III defects cannot retain an obturator and require a reconstruction that allow dental rehabilitation. Because the Okay classification is

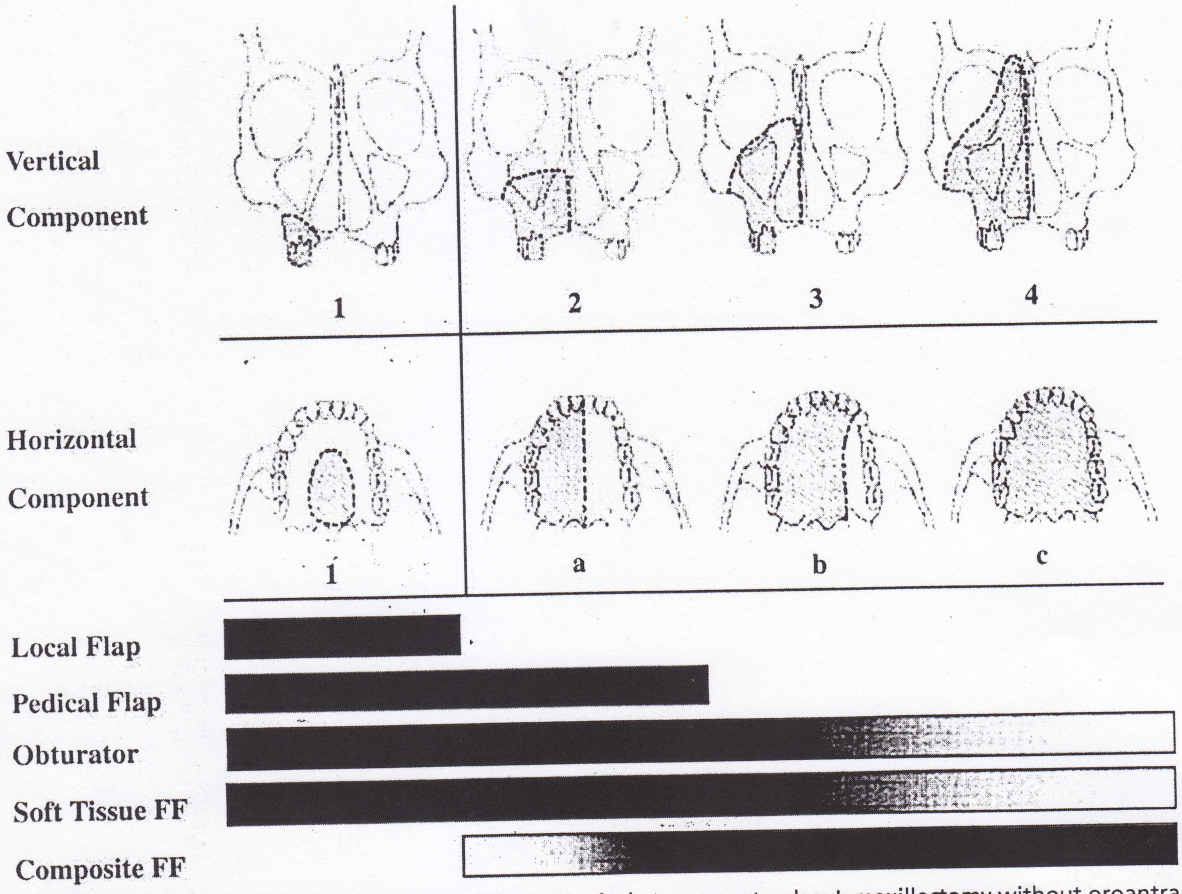

Fig. 2. The Brown classification of maxillary defects. Vertical component—class I: maxillectomy without oroantral fistula; class II: low maxillectomy; class III: high maxillectomy; and class IV: radical maxillectomy. Horizontal component—class a: less than or equal to half the hard palate and alveolus without involvement of the nasal septum; class b: greater than half of the hard palate and alveolus or involvement of the nasal septum; and class c: total hard palate and maxillary alveolus. FF, free flap. (*Reprinted from* Brown JS, Rogers SN, McNally DN, et al. A modified classifcation for the maxillectomy defect. Head Neck 2000;22:17–26; with permission.)

the only proposed scheme to focus on these outcomes, it is the one the authors favor. This classification is summarized in **Fig. 3**.

RECONSTRUCTIVE OPTIONS

Principles

As discussed previously, any reconstruction of the midface must, in addition to the restoration of form, restore as many of the functions of the native maxilla as possible. Speech, mastication, and swallowing must be re-established. Of prime importance to these functions, and especially to the former two, is dentition; any reconstructive option that prevents its restoration, therefore, should be avoided. For this reason, the reconstruction of an Okay class III defect with an obturator is counterproductive. Given the lack of abutment teeth in this defect, obturator retention is impossible, rendering the obturated patient an oral cripple. The same mode of thinking informs decisions for the reconstruction of Okay class II defects. In jurisdictions in which dental implantation is feasible, these defects benefit from bony reconstructive options that allow such implantation; in the absence of this ability, these defects should be obturated. Finally, the reconstruction of large maxillectomy defects with soft tissue also is counterproductive in this regard: large soft tissue flaps quickly become ptotic, leading to denture mobility and poor long-term results.

Obturation

Obturation benefits from being customizable, sturdy, and safe from the effects of local tissue factors, which, in patients who have received radiation previously, can be significant. The reconstruction of a maxillectomy defect with an obturator, however, subjects patients to constant foreign-body irritation, the need for significant manual dexterity, a reconstruction that is never stable, and a lower quality of life. This latter factor

Table 1
Reconstructive procedures by maxillectomy type, Cordeiro classification

Type	Defect	Soft Tissue	Bone Source
I	Limited maxillectomy	Radial forearm Rectus abdominis Temporalis	Iliac crest
II	Subtotal maxillectomy	Radial forearm Rectus abdominis Radial forearm osseocutaneous Temporalis	Rib Vascularized radial graft
IIIa	Total maxillectomy	Rectus abdominis Temporalis	Rib Iliac crest Calvarium
IIIb	Total with orbital exenteration	Rectus abdominis	—
IV	Orbitomaxillectomy	Rectus abdominis	Rib

Data from Cordeiro PG, Santamaria E: A classification system and algorithm for reconstruction of maxillectomy and midface defects. Plast Reconstr Surg 2000;105:2331–46.

is significant: patient satisfaction with obturators for the closure of palatal defects is significantly lower than with a fasciocutaneous free flap reconstructive paradigm.[5] As a result, in patients who can tolerate longer operative times, other reconstructive options warrant consideration.

Local and Regional Flaps

Smaller defects, especially of the palate, present less of a cosmetic and structural deformity than do defects after formal maxillectomies. In these defects, return to normal function is of pre-eminent concern. Local flaps often are used, with minimal morbidity to the patient. Split- and full-thickness skin grafts have been used in the past[12] but their usage is limited by donor-site morbidity (especially with split-thickness grafts) and poor wound-healing properties at the recipient site, especially evident in graft contracture. As a result, their usage has become significantly less common. This section discusses the use of the palatal island flap, the buccal fat pad, and flaps based on the temporalis system. Other, less commonly used flaps, such as the submental island flap,[13] are not discussed.

Palatal island flap

In 1977, Gullane and Arena first described the palatal island flap for the reconstruction of small palatal defects.[14] This flap, based on the greater palatine vessels, may be used to resurface defects up to 15 cm^2 and is capable of restoring the oronasal barrier in through-and-through defects (**Fig. 4**). It is limited by donor-site pain, but re-epithelialization of the donor site occurs within 3 months.[15]

Buccal fat pad

The buccal fat pad is a unique collection of adipocytes and stem cells within the buccal space, between the masseter and buccinators muscles, which has been used successfully for the reconstruction of smaller maxillectomy defects.[16,17] The vascular supply to this fat pad is surprisingly rich, allowing for rapid re-epithelialization and possibly for the use of this flap as lining in the setting of free, nonvascularized bone grafts.[18] The buccal fat pad is limited, however, by size; defects larger than 12 cm^2 are not amenable to this method of reconstruction.[17]

Temporalis muscle flap

When the resultant defect after a maxillectomy encompasses more than simply the palate, the structural functions of the maxilla and midface become paramount. Support of the cranium and, most especially, the remaining orbital contents, is required. Bony reconstructions are preferred; however, in patients in whom free tissue transfer is not a viable option, a rotational temporalis muscle flap, with or without nonvascularized bone, is a worthy surrogate. Because the natural curvature of the calvarium mimics that of the orbital floor, it can be used to reconstruct defects in the superior wall of the maxilla, with a rotational temporalis muscle flap for a vascularized bed. Access to the orbital floor, however, requires significant tunneling of the flap, putting the flap at risk for pressure-induced necrosis, or a partial

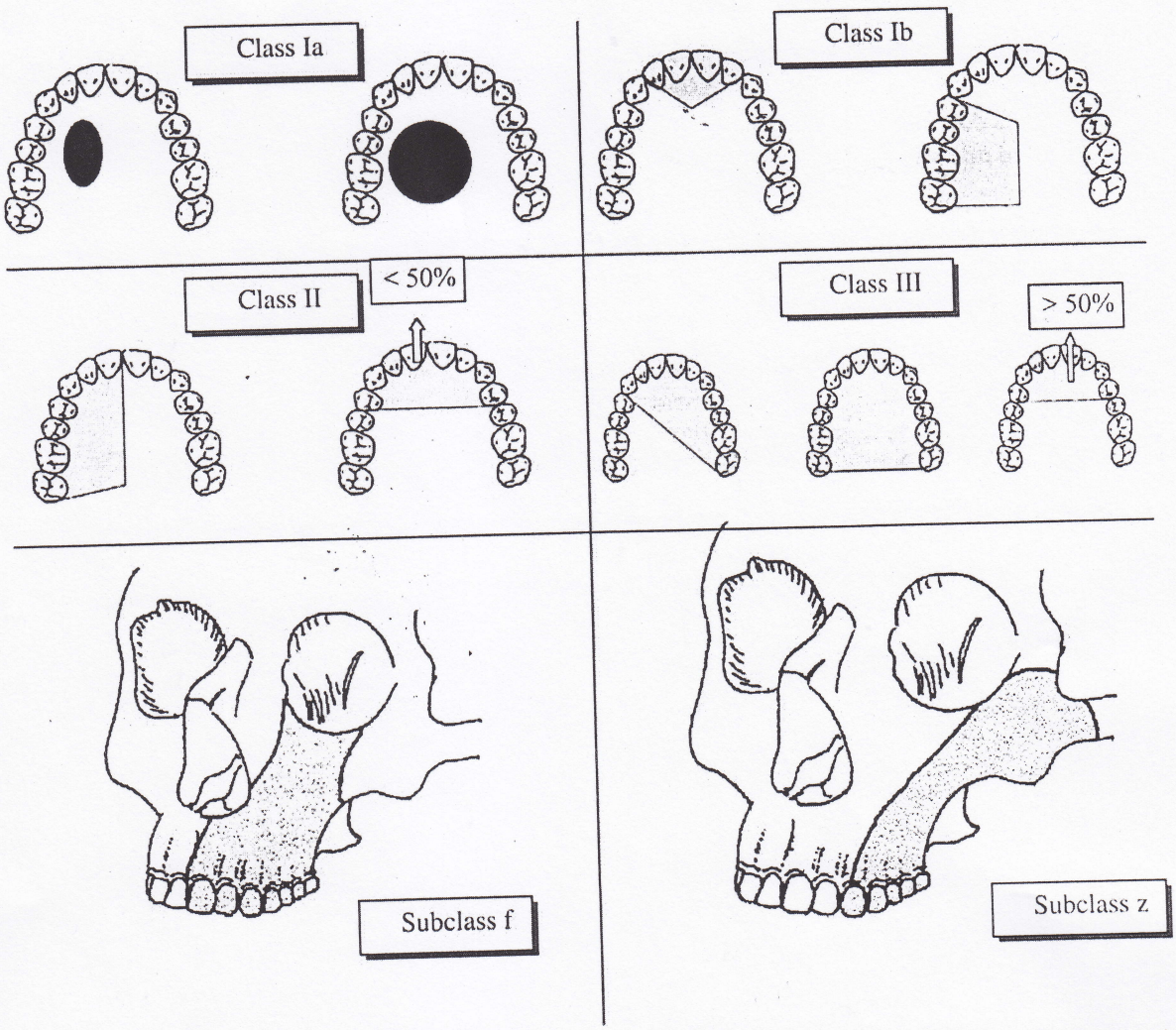

Fig. 3. The Okay classification of maxillary defects. Class Ia: no involvement of the tooth-bearing alveolus. Class Ib: preservation of both canines. Class II: resection of one canine or less than 50% of the hard palate. Class III: resection of both canines or greater than 50% of the hard palate. Subclass f: involvement of the orbital floor. Subclass z: involvement of the zygomatic arch. (*Reprinted from* Okay DJ, Genden E, Buchbinder D, et al. Prosthodontic guidelines for surgical reconstruction of the maxilla: a classification system of defects. J Prosthet Dent 2001;86:352–63; with permission.)

resection of the lateral portion of the zygomatic arch, risking weakening of the facial buttresses. In addition, because the frontal branch of the facial nerve crosses this arch, it also is placed at risk.

A temporoparietal osteofascial flap also has been described,[19,20] which provides the added benefits of allowing the transfer of vascularized bone to the orbital floor and affording a rotational flap with significantly less bulk than that harvested with the muscle flap, mitigating some of the difficulties discussed previously. The temporalis flap, however, suffers two significant disadvantages. For reconstructions of large palatal defects, in which the flap is asked to reach to the contralateral maxilla, there is a not insignificant rate of partial flap failure. In addition, the donor-site cosmetic defect is significant and, unfortunately, relatively unavoidable. Despite its drawbacks, the temporalis system, when used appropriately, has proved a particularly effective and robust donor site for the reconstruction of maxillary defects,[21,22] with a low overall failure rate and a reproducible ability to withstand postoperative radiotherapy.

Free Tissue Transfer

With the advent of microvascular techniques and free tissue transfer, the reconstruction of the maxilla and midface has become an area of significant research and innovation.[23–25] The donor-site armamentarium available to microsurgeons for the reconstruction of the maxilla and midface is

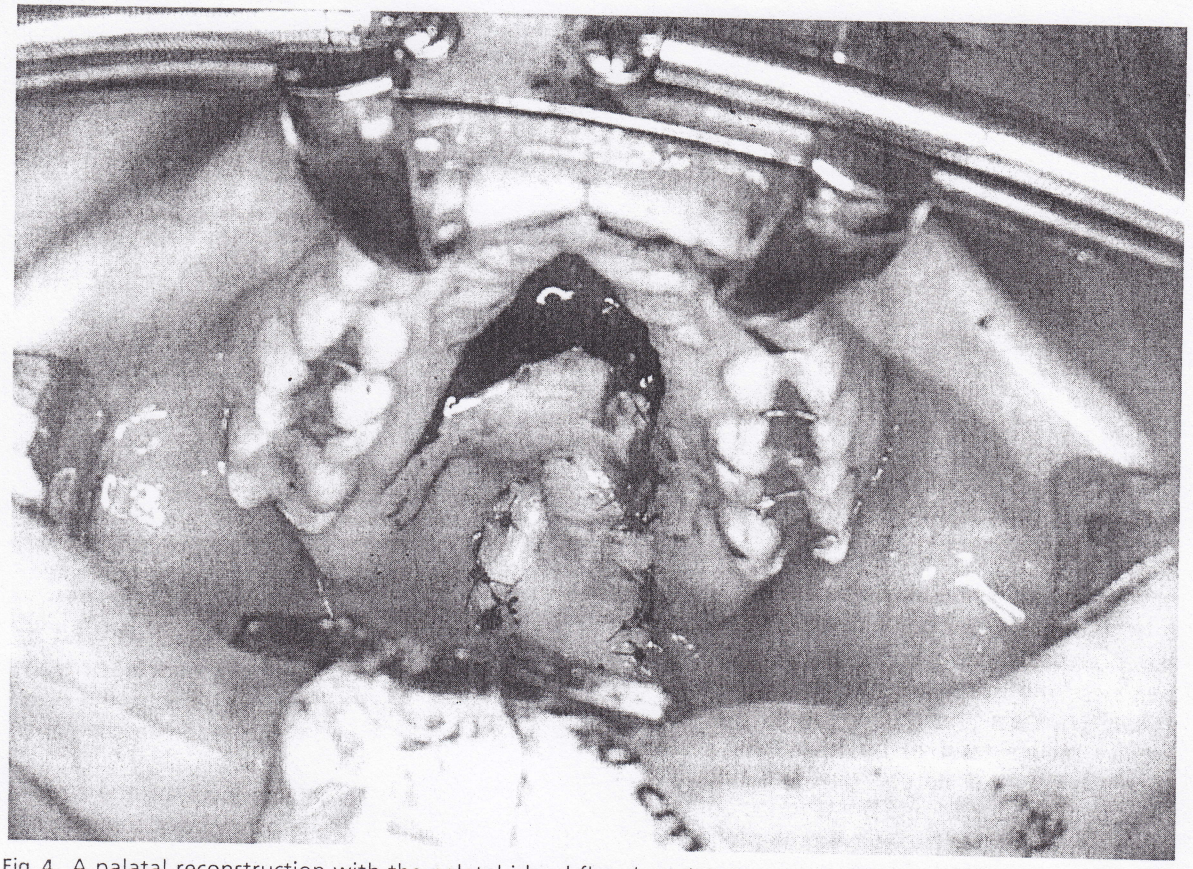

Fig. 4. A palatal reconstruction with the palatal island flap, based, in this patient, on the right greater palatine vascular pedicle. The anterior portion of this flap is left open to heal by secondary intention.

astonishingly diverse. Depending on the defect, fasciocutaneous, osteocutaneous, myocutaneous, myogenous, and myo-osseous flaps all are used in the reconstruction of maxillary defects.

The Radial Forearm System

There are many features of the radial forearm system that make it a good flap for head and neck reconstruction: its anatomy is relatively constant, its vascular pedicle long and of good caliber, and its harvest comparatively easy. It is primarily harvested, however, as a fasciocutaneous flap and, therefore, is suited most appropriately for smaller, less structurally significant defects. Its primary use as a fasciocutaneous flap has been for the reconstruction of Okay class Ia and Ib defects, in which the functional deficit engendered by the lack of separation of the oral and nasal cavities is the primary reconstructive concern. In that setting, as discussed previously, it offers equivalent patient satisfaction with taste, aesthetic appearance, and mastication as an obturator but affords patients improved satisfaction with social interaction, speech quality, comfort, and convenience.[5]

Despite the possibility of significant donor-site morbidity, including radial bone fracture,[26] the radial forearm system also has been harvested as an osseofasciocutaneous flap for the reconstruction of subtotal maxillectomy defects. In this setting, the radial forearm skin island is wrapped around the harvested portion of the radial bone, in a "sandwich" configuration. The osseous component is used for the reconstruction of the resected maxillary buttresses; the folded skin paddle reconstructs the oral and nasal lining.[10,26]

The Rectus Abdominis

What the rectus abdominis free flap lacks in vascularized bone, it makes up for in volume. A significant volume of muscle and adipose tissue can be harvested with this flap in addition to multiple, independent skin islands. Based on the deep inferior epigastric artery and its vein, and its cutaneous perforators, this flap also affords ease of harvest, constant anatomy, and a reliable vascular pedicle. Bone for the reconstruction of the orbital floor or maxillary buttresses, however, must be nonvascularized given the lack of available bone stock in the donor site. This prevents later

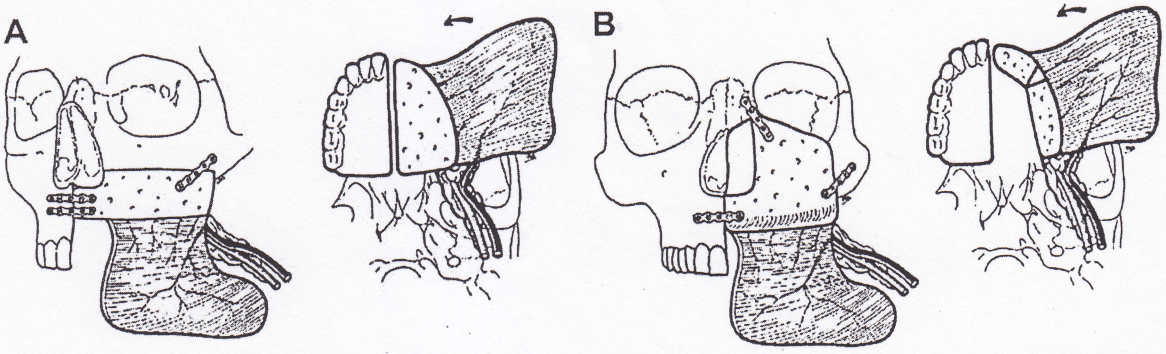

Fig. 5. (*A*) Reconstruction of a low maxillectomy defect using a horizontally oriented iliac crest free flap. (*B*) Reconstruction of a middle-height maxillectomy defect using a vertically oriented iliac crest free flap. Note that, in this case, the internal oblique muscle is rotated medially to close the resultant palatal defect. (*Reprinted from* Brown JS. Deep circumflex iliac artery free flap with internal oblique muscle as a new method of immediate reconstruction of maxillectomy defect. Head Neck 1996;18:412–21; with permission.)

osseointegrated dental implantation, but the flap has been successfully combined with the use of these nonvascularized bone grafts.[27] Although experience with this flap in the reconstruction of maxillary defects has been extensive, and aesthetic results tend to be favorable,[27,28] the authors do not favor its use, given its inability to offer structural support and the tendency of cutaneous portions of this flap to become ptotic.

The Fibula

The fibula has been used as a microvascular reconstructive option for the mandible and the maxilla; the bulk of experience in this flap has been with the former.[29] The fibula benefits from one of the greatest sources of bone stock available to the reconstructive microsurgeon: its bone is long, perfused by its nutrient arteries and a rich periosteal system—allowing for multiple osteotomies, and can accept osseointegrated dental implants. In addition, it can be accessed using a two-team approach and may be harvested as an osseous or an osseocutaneous flap. Its limitations, however, include a short vascular pedicle necessitating a vein graft in a large proportion of patients requiring the reconstruction of total maxillectomy defects, a not negligible donor-site functional morbidity, and the fact that modeling a straight long bone into the curved architecture of the maxilla is not always an easy undertaking.[24,25] In addition, modeling it to reconstruct the 3-D square frustum that is the maxilla is nearly impossible; thus, as the maxillectomy defect increases in complexity, the usefulness of the fibular free flap decreases.[30,31]

The Iliac Crest

The bone stock available from the iliac crest overcomes many of the limitations described previously. Its bone is curved; it can be harvested with a significant muscular component if the internal oblique muscle is left attached; and it can be used to reconstruct low, middle, or high maxillectomy defects. For low defects, the iliac crest is oriented horizontally, reconstructing the curvature of the palate and maxillary alveolus (**Fig. 5**A). For middle defects involving the structures of the midface, the flap may be oriented vertically, reconstructing the maxillary buttress (**Fig. 5**B). In this situation, the internal oblique muscle is rotated internally and is itself used to close the palatal defect.[32] Re-epithelialization of this muscle is relatively rapid. Finally, for high

Fig. 6. Reconstruction of an Okay class II_{fz} defect with a vertically oriented, split iliac crest graft. Nonvascularized bone was used to reconstruct the orbital floor and was plated to the vascularized portion of the graft. The internal oblique muscle is seen at the bottom of the picture; this was rotated posteriorly to reconstruct the palatal defect.

defects, the muscle itself may be used to obliterate the orbital defect. The bone stock available from the iliac crest also is sturdy enough to accept osseointegrated implants.[24,25,32]

Unfortunately, despite the benefits inherent to this flap, it has its limitations: the internal oblique muscle is comparatively tethered relative to the bone, and the length of the deep circumflex iliac artery and vein pedicle often is prohibitively short (approximately 4–5 cm), especially for higher defects. Although better than the long-bone options, the bone from the iliac crest is not ideally suited to the shape of the maxilla, and the flap often suffers from excess bulk. In addition, this donor site is fraught with significant morbidity, including pain, early difficulties with ambulation, and late risks for abdominal hernias.

A vertically oriented iliac crest reconstruction is shown in **Fig. 6**.

The Scapular System

Since its description in the mid-1980s as a potential microvascular donor site for head and neck reconstruction,[33,34] the scapular system has offered a plethora of reconstructive options. There are two osseous flaps that can be harvested off the vascular pedicle that this system offers. Classically, the lateral border of the scapula has been harvested based on a nutrient artery branch off the circumflex scapular system. This flap has the advantage of attached muscle with which it can be harvested, and a skin island, which is relatively mobile. The pedicle is short and the harvested

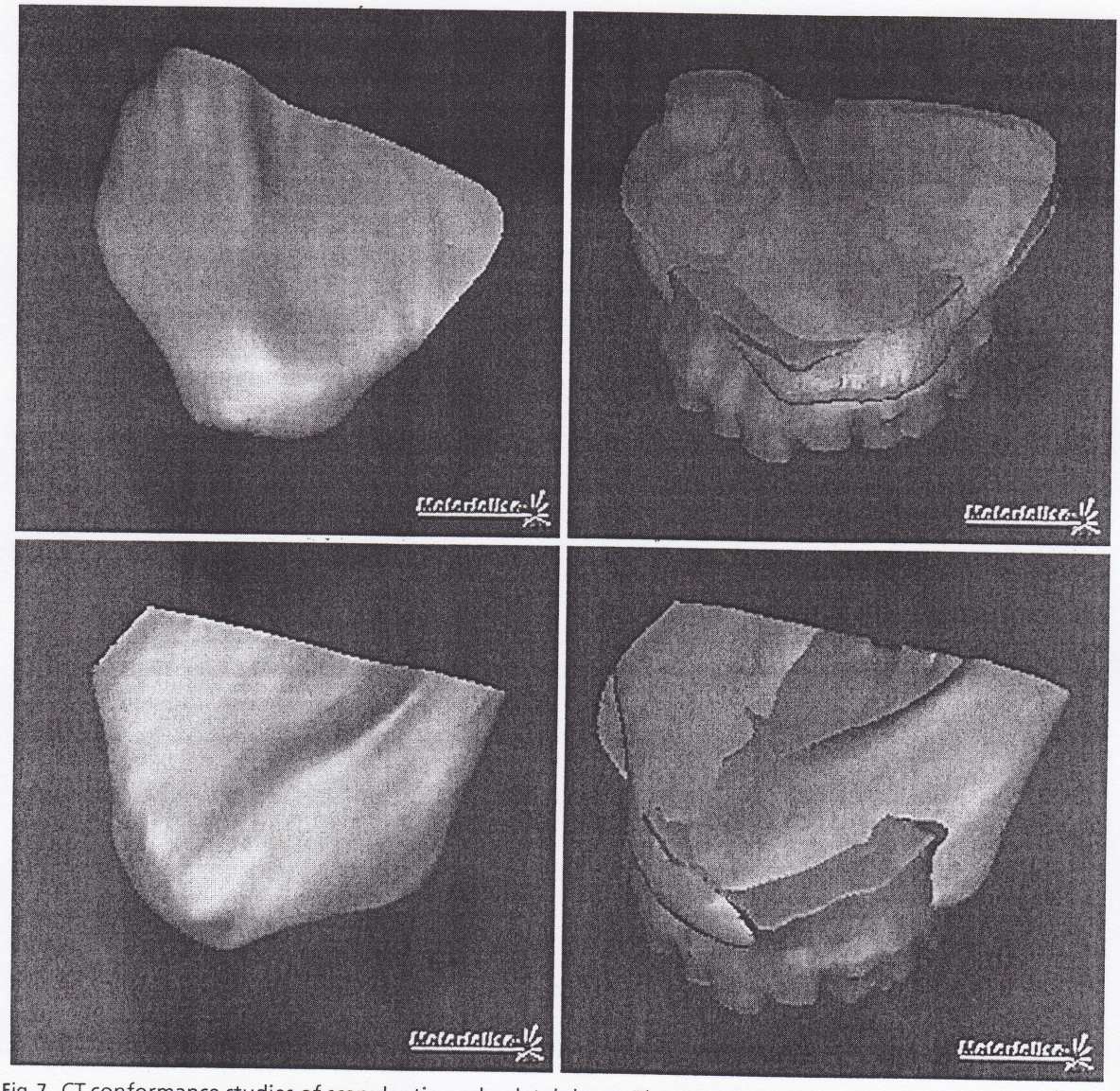

Fig. 7. CT conformance studies of scapular tip and palatal shape. The upper row shows conformance with the left scapular tip, the lower row with the right. In this patient, mean conformance distance was 2.04 mm (range 0.19–6.56 mm).

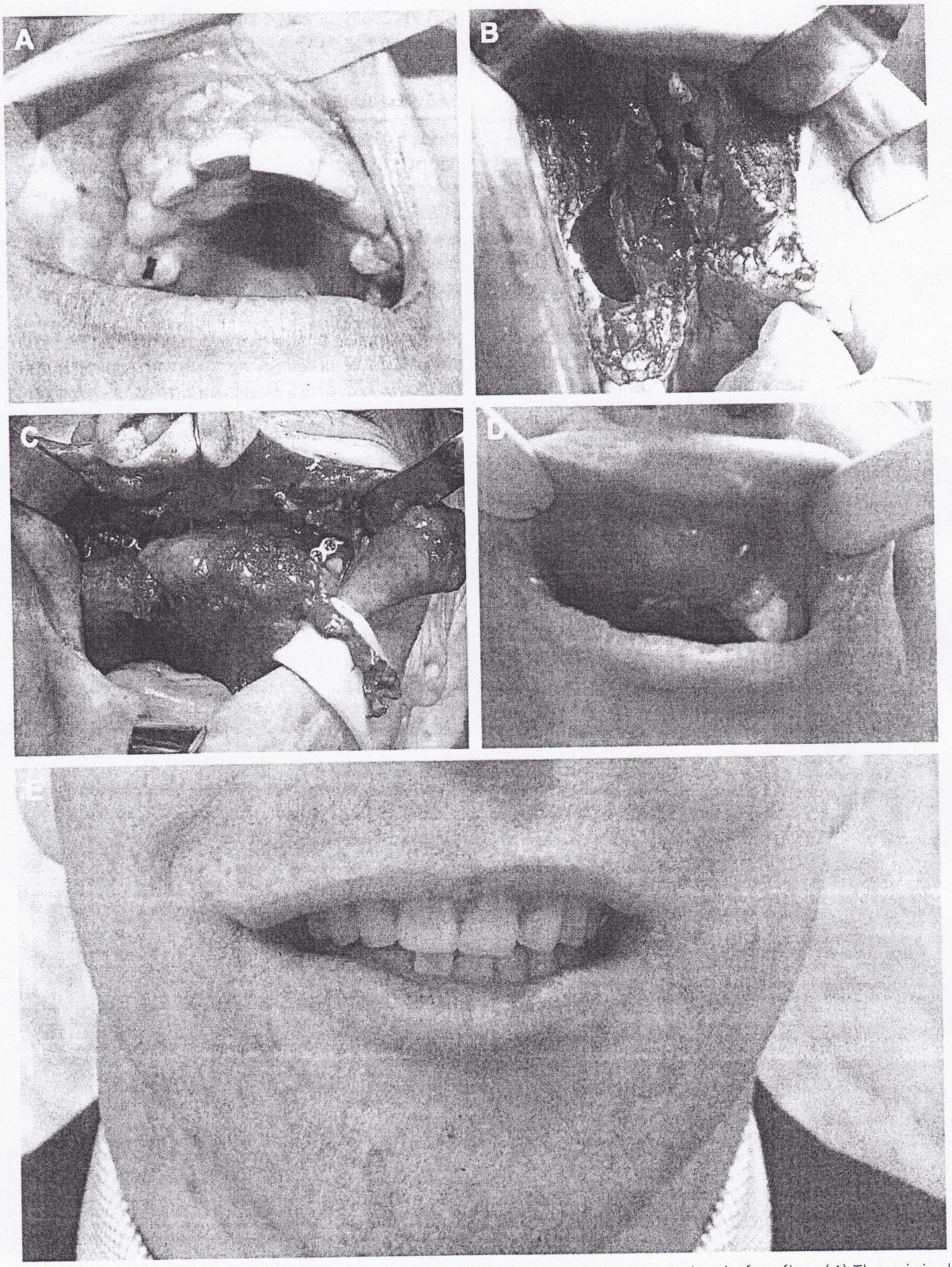

Fig. 8. Reconstruction of an Okay class II defect with a horizontally oriented scapular tip free flap. (*A*) The original osteosarcoma. (*B*) The defect after resection of the primary lesion. (*C*) Reconstruction with a horizontally oriented scapular tip; the angular artery pedicle is seen at the right of the image. (*D*) The reconstructed defect after mucosalization of the teres major muscle. (*E*) The fully rehabilitated result; this patient opted for denture reconstruction as opposed to dental implantation.

bone is rectangular, however. A second osseous flap was described by Coleman and Sultan in 1991.[35] Based on the angular artery, which branches off the serratus muscle branch of the thoracodorsal artery or off the main trunk itself with approximately equal frequency,[24] this flap centers on the scapular tip and offers multiple advantages over the standard scapular flap. The vascular pedicle is long (10–12 cm), a separate skin island can be harvested based on thoracodorsal artery perforators, the teres major muscle can be harvested along with the scapular tip, and the bone is ideally suited for reconstruction of vertical and horizontal maxillary defects (see discussion later). There is a rich collateral plexus between the angular artery and the circumflex scapular artery, and direct cutaneous branches off the thoracodorsal artery itself, allowing myriad reconstructive options.

More than any other flap discussed, the scapula is ideally suited for the reconstruction of the maxilla. The shape of the tip of the scapula conforms to the curvature of the maxilla nearly identically. In CT conformational studies, performed at the authors' institution, the average variance between the shape of the scapular tip and that of the palate is approximately 2.13 mm (range 0.21 to 8.51 mm), making the scapular tip a nearly perfect reconstructive modality for the maxilla (**Fig. 7**).

Similar to reconstruction using the iliac crest, the scapula can be positioned horizontally or vertically; the teres major muscle may be rotated medially to reconstruct palatal defects in the latter setting, in much the same way that the internal oblique is used in the iliac crest reconstructions. In addition, the midportion of the scapular body itself carries a curve similar to that of the orbital floor and, therefore, can be used as a nonvascularized graft for its reconstruction. Other benefits of this donor site over others (discussed previously) include minimal functional morbidity, an exceedingly long vascular pedicle, the ability to design multiple skin flaps based on the scapular and parascapular branches of the circumflex scapular artery and the thoracodorsal artery perforators, and a well-hidden scar. Limitations are few: the flap cannot be harvested in a two-team approach and often requires positioning that may make the initial ablative resection more difficult **Fig. 8**.

To date, the authors' institution has performed 29 reconstructions of maxillectomy defects with the angular artery/scapular tip free flap. (The first 14 of these have been reported in previous publications.)[36] Of these reconstructions, 24 were performed for malignant disease and five for benign disease. Fourteen patients had Okay class III defects, 10 class II, and 2 class I. Three patients had intact palates, with resections only of the orbital rim or zygomatic complex (a defect not classifiable using the Okay system). Mean hospital stay was 10.5 days, and three patients had significant medical complications (pulmonary embolus, respiratory failure, and death from an acute myocardial infarction). Four patients had donor-site seromas, and two required treatment for facial wound infections. No vein grafts were needed, speaking to the adequate length of the harvestable vascular pedicle. Six patients had a shallow vestibulobuccal sulcus, which was treated during a second procedure with a vestibuloplasty and split-thickness skin graft. Five patients suffered postoperative ectropion, and three had epiphora postoperatively; both complications were treated successfully in second procedures.

Eighteen patients agreed to undertake the Disabilities of the Arm, Shoulder and Head questionnaire.[37] On this questionnaire—a joint initiative of the American Academy of Orthopaedic Surgeons, the Council of Musculoskeletal Specialty Societies, and the Institute for Work & Health (in Toronto)—the normative score is 10.1. In the patients who completed the questionnaire, the mean score also was 10.1, supporting minimal donor-site functional morbidity from the harvest of the scapular tip.

Fourteen patients were able to return to a normal diet; 13 were able to wear dentures. Because of significant financial constraints surrounding the procedure, only two patients progressed to an attempt at osseointegrated implantation. One was implanted successfully and one was found to have inadequate bone stock.

The authors' experience has confirmed the significant usefulness gained from the use of free vascularized tissue from the scapular system in the reconstruction of maxillectomy defects. This system avoids many of the limitations inherent in other donor sites while maintaining or improving upon their advantages.

SUMMARY

The 3-D structure of the maxilla and its fundamental role in the structural and functional integrity of the face makes its reconstruction challenging and of primary import to a patient's aesthetic appearance, postoperative function, and overall satisfaction. There are myriad reconstructive options for maxillectomy defects, depending on the size and location of the defect. In keeping with the complexity of this area in the head and neck, no single classification encompasses all the possible defects concisely and perfectly reproducibly. Similarly, no single reconstructive option

can be used for every defect. For larger defects, however, the bone-muscle flaps—namely, the iliac crest and the scapular tip—seem most ideally suited for this region of head and neck reconstruction.

REFERENCES

1. Kaneda T, Minami M, Kurabayashi T. Benign odontogenic tumors of the mandible and maxilla. Neuroimaging Clin N Am 2003;13:495–507.
2. Underhill TE, Katz JO, Pope TLJ, et al. Radiologic findings of diseases involving the maxilla and mandible. Am J Roentgenol 1992;159:345–50.
3. Weber AL, Bui C, Kaneda T. Malignant tumors of the mandible and maxilla. Neuroimaging Clin N Am 2003;13:509–24.
4. Keen W. The surgical operations on president Cleveland in 1893. Philadelphia: GW Jacobs & Co; 1917.
5. Genden E, Wallace DI, Okay DJ, et al. Reconstruction of the hard palate using the radial forearm free flap: indications and outcomes. Head Neck 2004; 26:808–14.
6. Öhngren LG. Malignant tumors of the maxilloethmoidal region. Acta Otolaryngol 1933;19(Suppl): 101–6.
7. Spiro RH, Strong EW, Shah JP. Maxillectomy and its classification. Head Neck 1997;19:309–14.
8. Aramany M. Basic principles of obturator design for partially edentulous patients. Part I: classification. J Prosthet Dent 1978;40(5):554–7.
9. Brown JS, Rogers SN, McNally DN, et al. A modified classifcation for the maxillectomy defect. Head Neck 2000;22:17–26.
10. Cordeiro PG, Santamaria E. A classification system and algorithm for reconstruction of maxillectomy and midface defects. Plast Reconstr Surg 2000; 105:2331–46.
11. Okay DJ, Genden E, Buchbinder D, et al. Prosthodontic guidelines for surgical reconstruction of the maxilla: a classification system of defects. J Prosthet Dent 2001;86:352–63.
12. Rhee PH, Friedman CD, Ridge JA, et al. The use of processed allograft dermal matrix for intraoral resurfacing: an alternative to split thickness skin grafts. Arch Otolaryngol Head Neck Surg 1998;124:1201–4.
13. Genden E, Buchbinder D, Urken M. The submental island flap for palatal reconstruction: a novel technique. J Oral Maxillofac Surg 2004;62:387–90.
14. Gullane PJ, Arena S. Palatal island flap for reconstruction of oral defects. Arch Otolaryngol Head Neck Surg 1977;103:598–9.
15. Moore BA, Magdy E, Netterville JL, et al. Palatal reconstruction with the palatal island flap. Laryngoscope 2003;113:946–51.
16. Neder A. Use of buccal fat pad for grafts. Oral Surg Oral Med Oral Pathol 1983;55:349–50.
17. Arce K. Buccal fat pad in maxillary reconstruction. Atlas Oral Maxillofac Surg Clin North Am 2007;15: 23–32.
18. Zhong LP, Chen GF, Fan LJ, et al. Immediate reconstruction of maxilla with bone grafts supported by pedicled buccal fat pad graft. Oral Surg Oral Med Oral Pathol 2004;97:147–54.
19. Choung PH, Nam IW, Kim KS. Vascularized bone grafts for mandibular and maxillary reconstruction: the pariental osteofascial flap. J Craniomaxillofac Surg 1991;19:235–42.
20. Parhiscar A, Har-El G, Turk JB, et al. Temporoparietal osteofascial flap for head and neck reconstruction. J Oral Maxillofac Surg 2002;60:619–22.
21. Abubaker AO, Abouzgia MB. The temporalis muscle flap in reconstruction of intraoral defects: an appraisal of the technique. Oral Surg Oral Med Oral Pathol 2002;94:24–30.
22. Ward B. Temporalis system in maxillary reconstruction: temporalis muscle and temporoparietal galea flaps. Atlas Oral Maxillofac Surg Clin North Am 2002;15:33–42.
23. Coskunfirat OK, Wei FC, Huang WC, et al. Microvascular free tissue transfer for treatment of osteoradionecrosis of the maxilla. Plast Reconstr Surg 2005; 115:54–60.
24. Dalgorf D, Higgins K. Reconstruction of the midface and maxilla. Curr Opin Otolaryngol Head Neck Surg 2008;16:303–11.
25. Futran ND, Mendez E. Developments in reconstruction of midface and maxilla. Lancet Oncol 2006;7: 249–58.
26. Andrades P, Rosenthal EL, Carroll WR, et al. Zygomaticomaxillary buttress reconstruction of midface defects with the osteocutaneous radial forearm free flap. Head Neck 2008;30:1295–302.
27. Bianchi B, Bertolini F, Ferrari S, et al. Maxillary reconstruction using the rectus abdominis free flap and bone grafts. Br J Oral Maxillofac Surg 2006;44: 526–30.
28. Browne JD, Burke AJ. Benefits of routine maxillectomy and orbital reconstruction with the rectus abdominis free flap. Otolaryngol Head Neck Surg 1999;121:203–9.
29. Hidalgo D. Fibular free flap: a new method of mandible reconstruction. Plast Reconstr Surg 1989;84:71–9.
30. Futran ND, Wadsworth JT, Villaret D, et al. Midface reconstruction with the fibula free flap. Arch Otolaryngol Head Neck Surg 2002;128:161–6.
31. Kim DD, Dreher MA. The fibula free flap in maxillary reconstruction. Atlas Oral Maxillofac Surg Clin North Am 2007;15:13–22.
32. Brown JS. Deep circumflex iliac artery free flap with internal oblique muscle as a new method of immediate reconstruction of maxillectomy defect. Head Neck 1996;18:412–21.

33. dos Santos LF. The vascular anatomy and dissection of the free scapular flap. Plast Reconstr Surg 1984; 73:599–603.
34. Swartz WM, Banis JC, Newton ED, et al. The osteocutaneous scapular free flap for mandibular and maxillary reconstruction. Plast Reconstr Surg 1986; 77:530–45.
35. Coleman JJ, Sultan MR. The bipedicled osteocutaneous scapula flap: a new subscapular system flap. Plast Reconstr Surg 1991;87:682–92.
36. Clark JR, Vesely M, Gilbert RW. Scapular angle osteomyocutaneous flap in postmaxillectomy reconstruction: defect, reconstruction, shoulder function, and harvest technique. Head Neck 2008;30:10–20.
37. Hudak PL, Amadio PC, Bombardier C, The Upper Extremity Collaborative Group. Development of an upper extremity outcome measure: the DASH (Disabilities of the Arm, Shoulder, and Head). Am J Ind Med 1996;29:602–8.